

Predictable Immediate Dentures

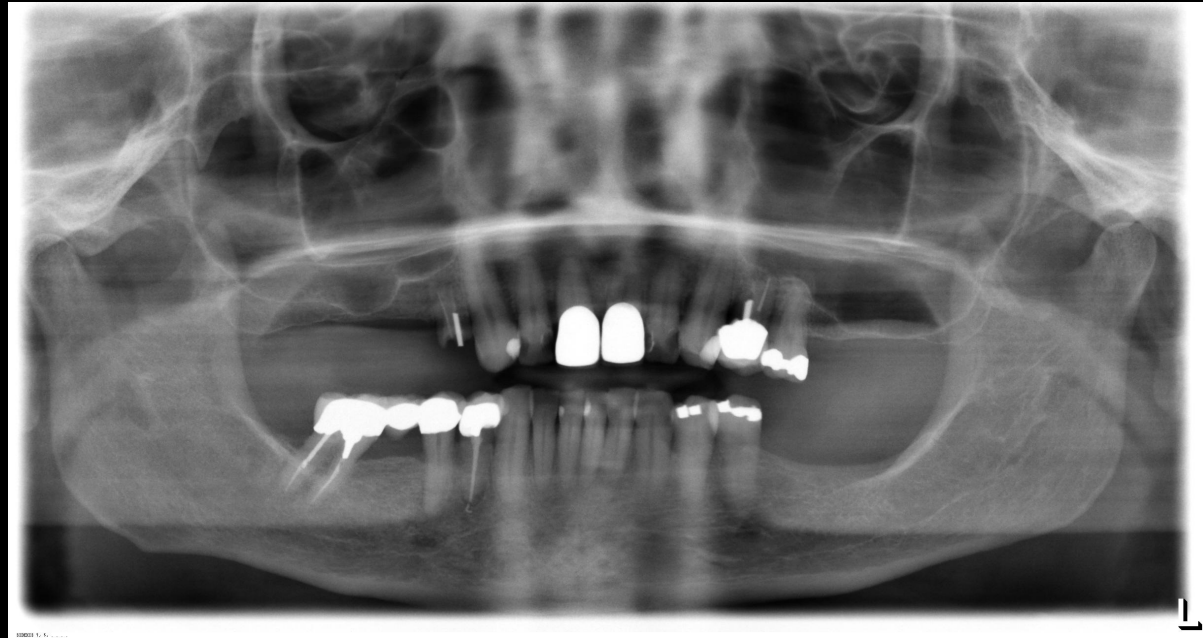
Dr. Sid Parker

7/20/17

Pre-op Pan

High Risk Biomechanics and
Perio

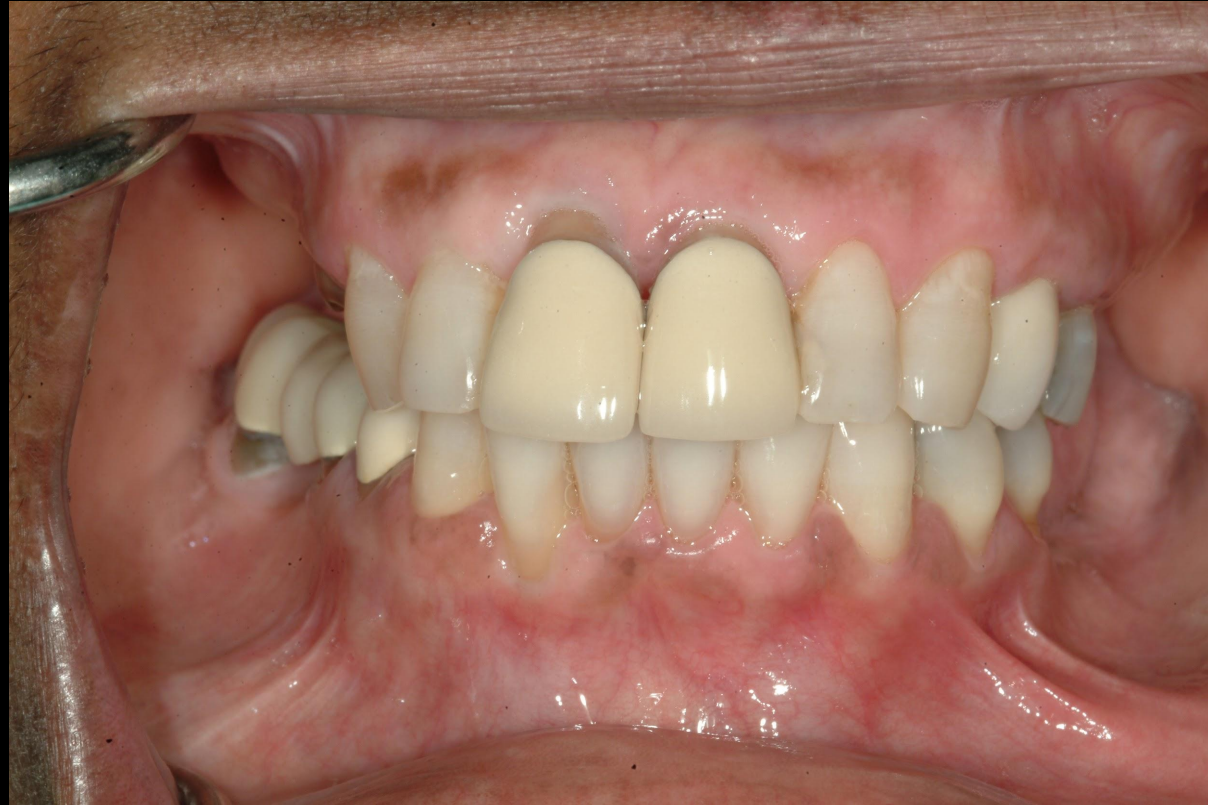Patient declined option of saving
any remaining maxillary teeth
and insisted on full upper
denture.



Closed Retracted - MIP

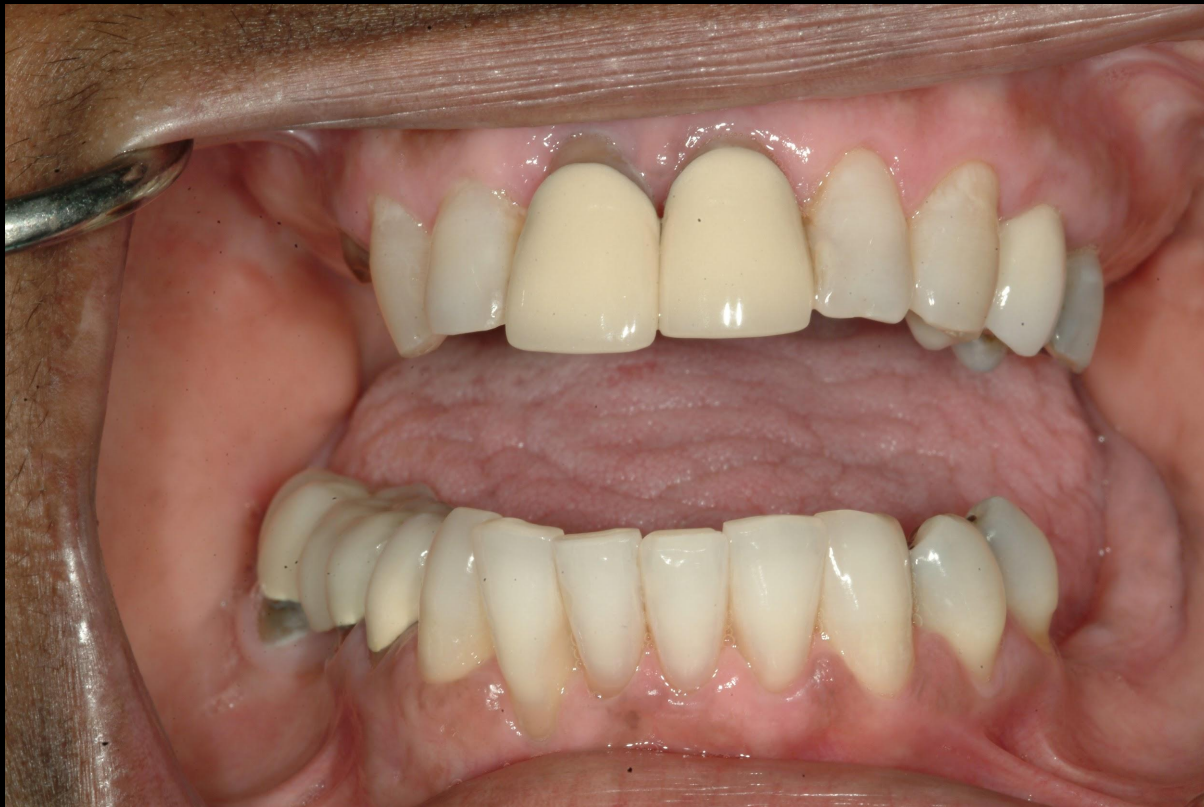-Limited occlusal clearance on posterior right.

-CI III mobility teeth 8 & 9 from decreased bone support

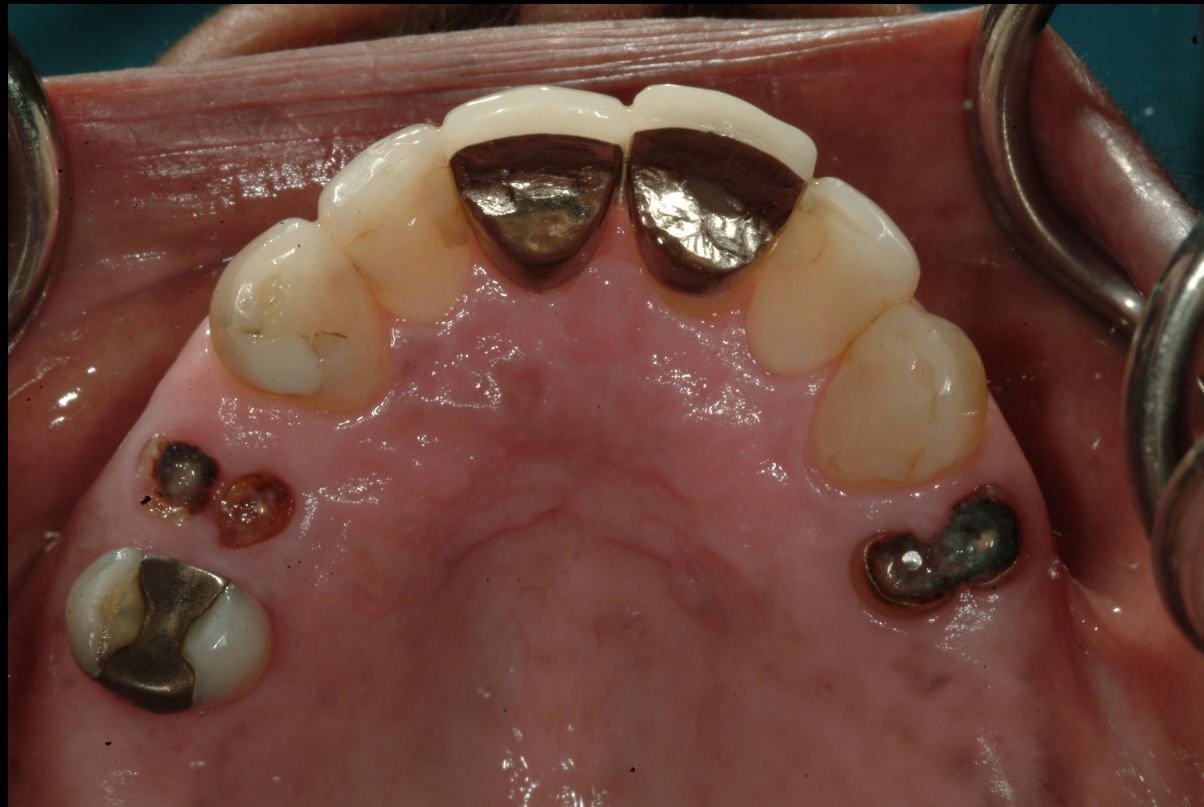

Open retracted

Lower occlusal plane close to
level



Maxillary occlusal



-Medium Lip Dynamics on
Maxillary yielding more favorable
esthetic outcome



-Many people are resistant to smile in photographs after missing teeth for a long time and for this reason multiple photos on different visits may be necessary.

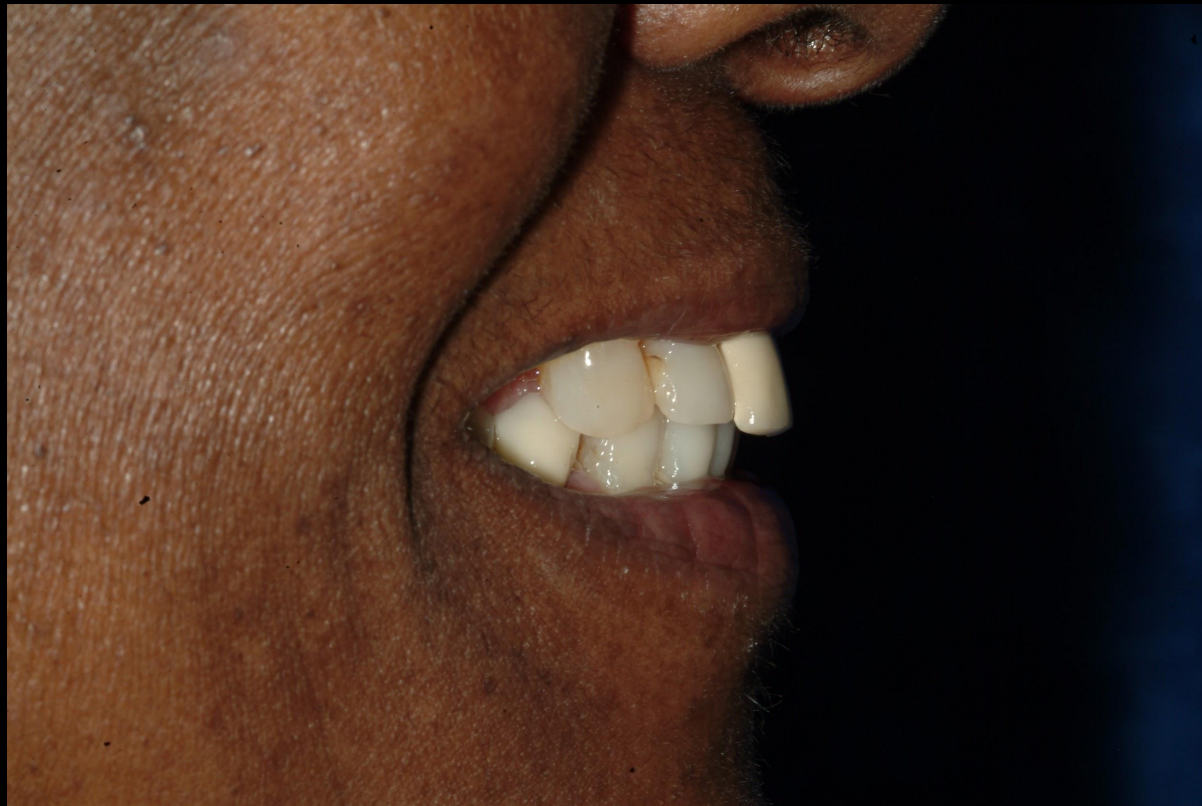-Midline canted to patients right

-Need to move midline 2mm to patient left and this should coincide with facebow

-Make incisal edge #9 1mm longer than #10 for vertical position and copy facial position #10 for horizontal position



Teeth 8 & 9 supererupted and
proclined too far facially



Retractors used to show how levelness of existing occlusal plane.

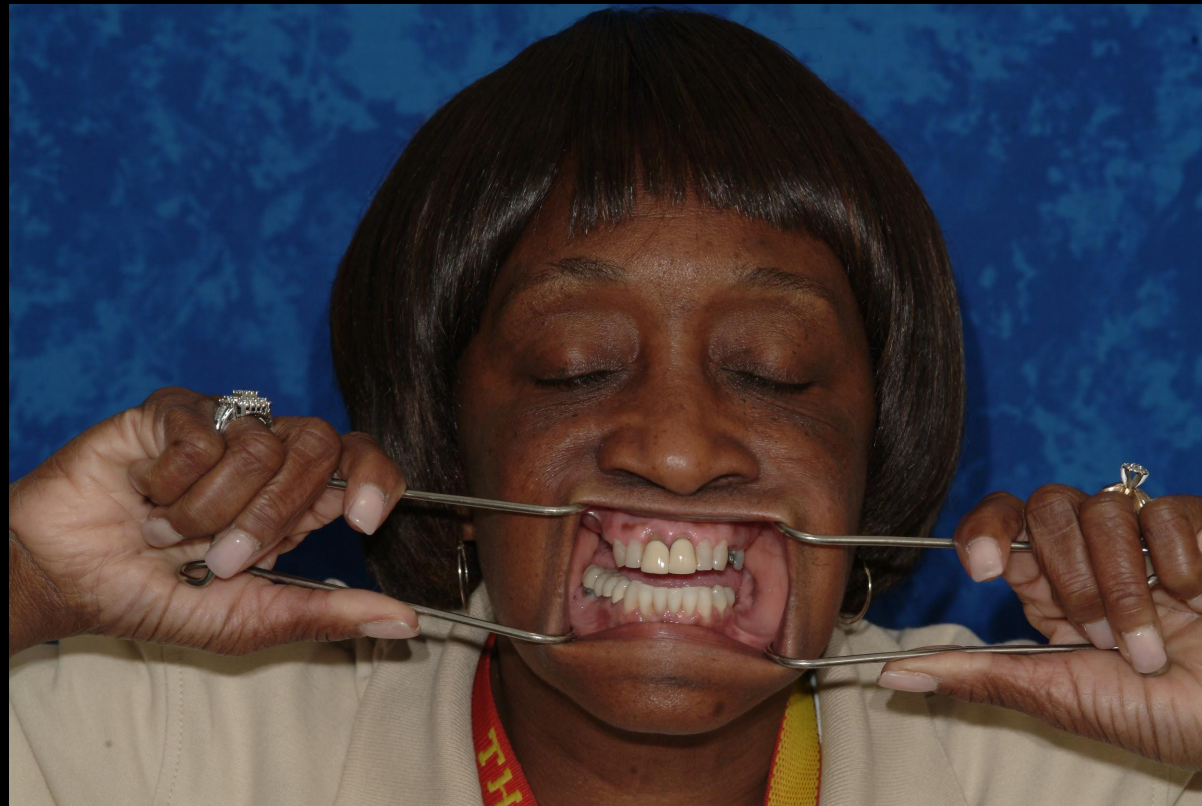Patient is not open enough and this photo is undiagnostic.

See next slide for proper photo



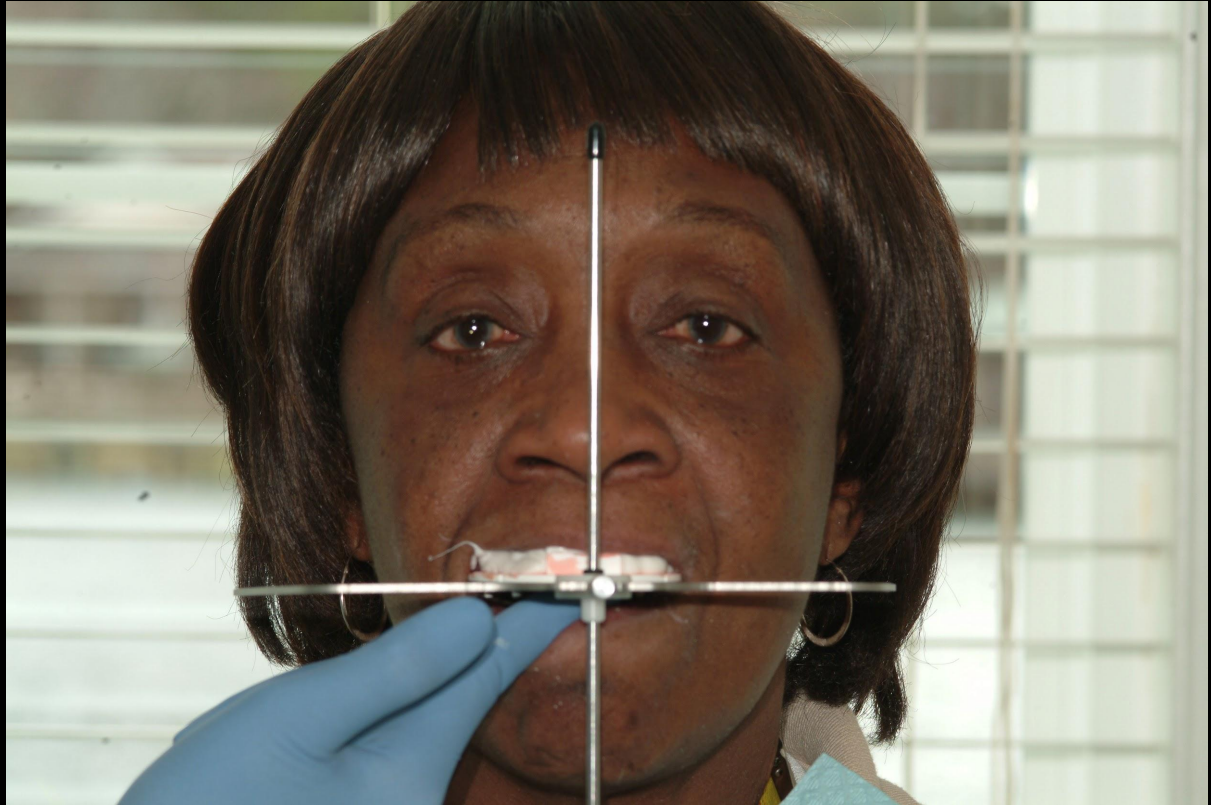Use retractors to determine how level existing occlusal plane.

This should match what you are seeing on the facebow table on articulator.

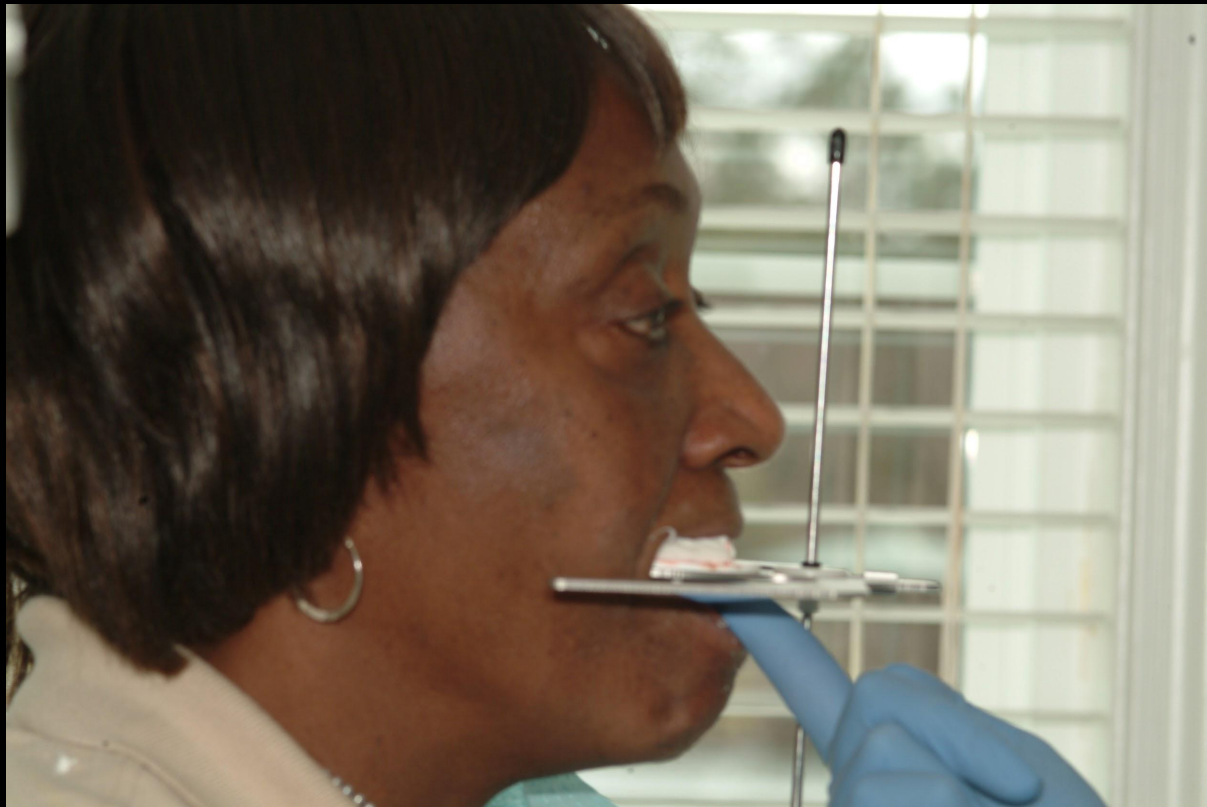

Kois facebow

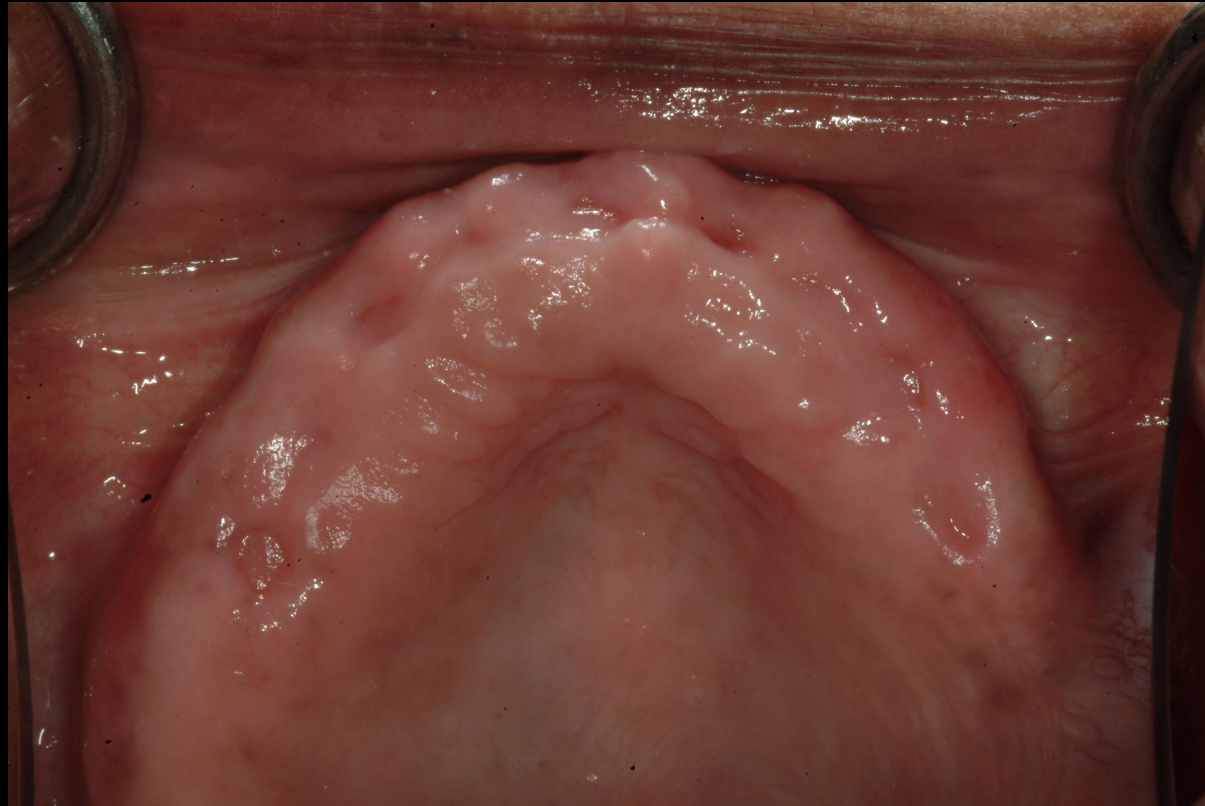Helps to photograph with a level line in the background to use for comparison i.e. Blinds.



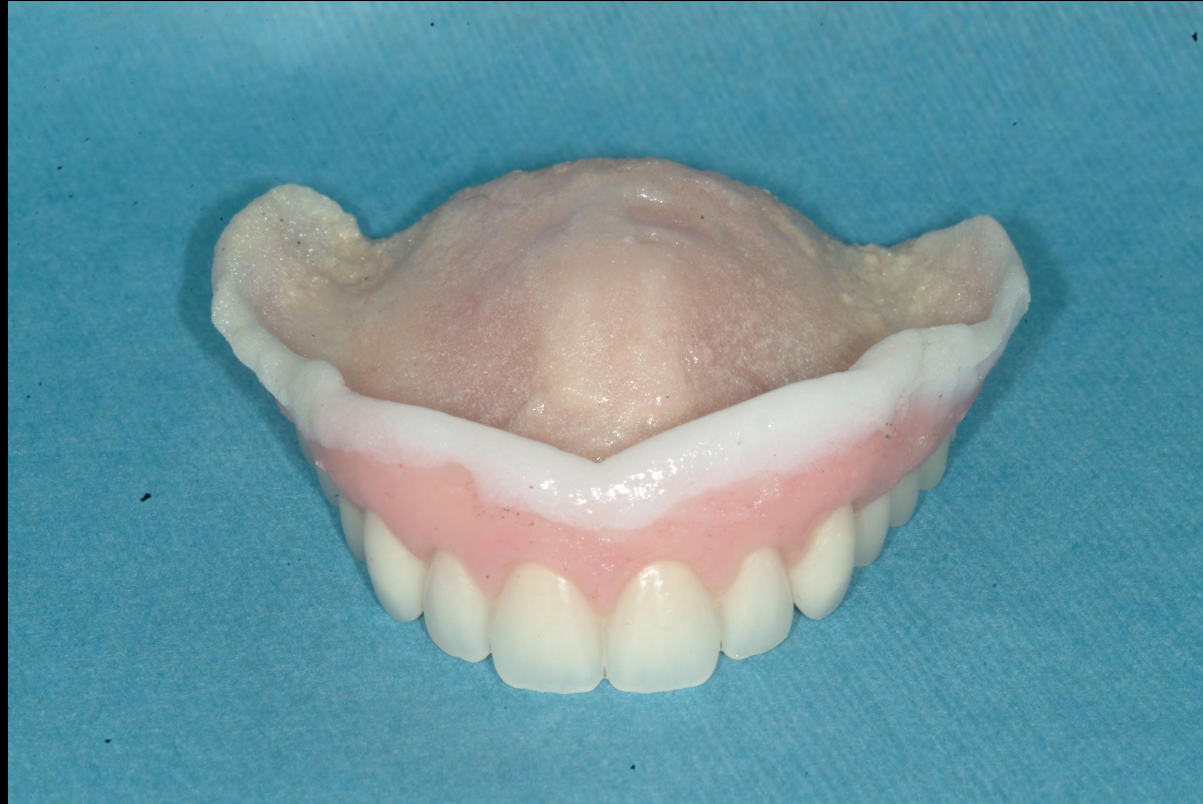Should be also level
anterior-posteriorly.



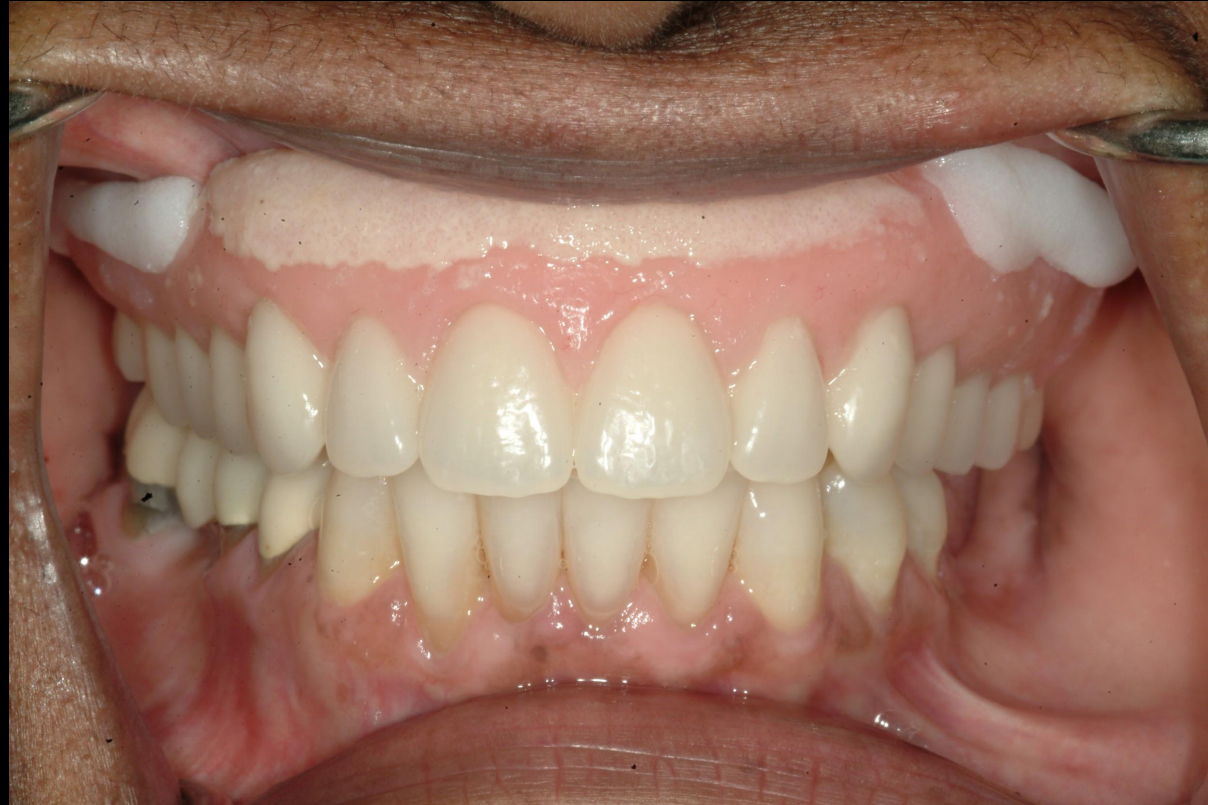Allow 6 months of tissue healing
before fabricating final denture.



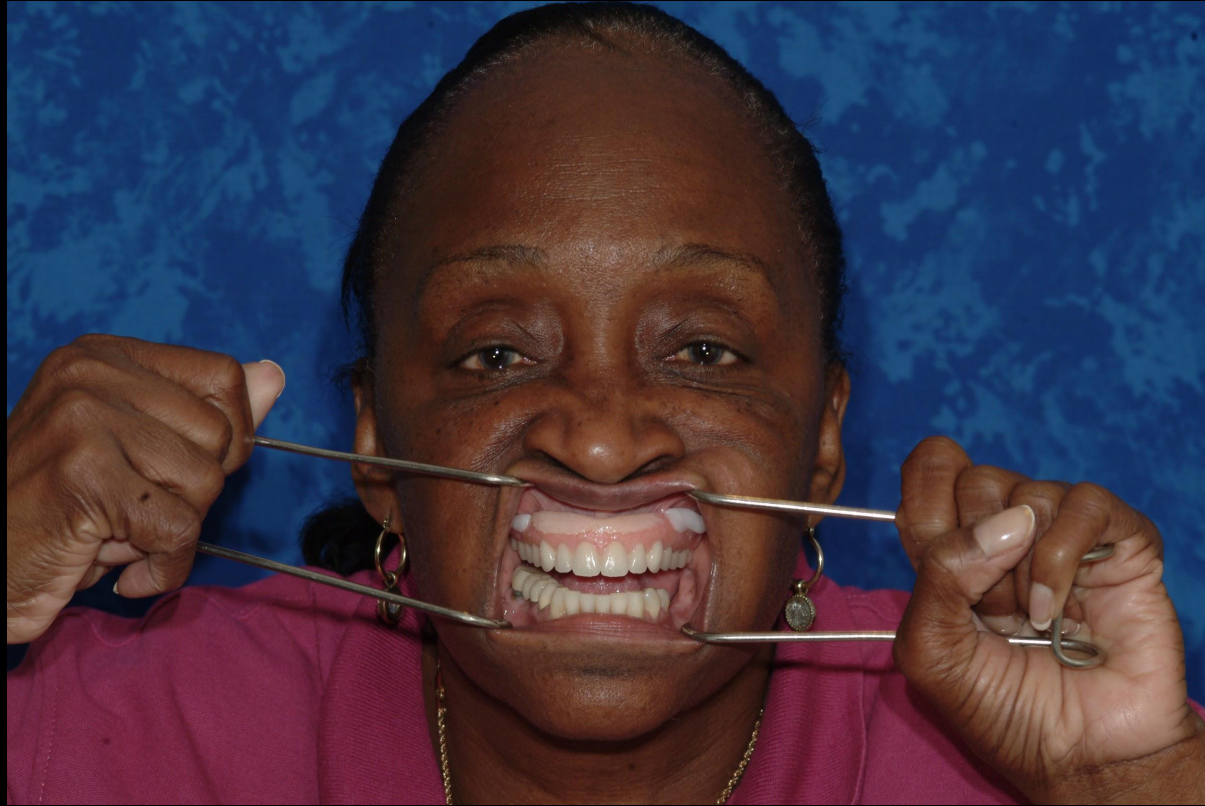Temporary Denture with
Hydrocast during 6 month
healing phase.



Lingualized occlusion with no
anterior tooth contact in CR.



Temporary Denture with
Hydrocast with more level plane.



1 week post op check



Anterior teeth more upright and
less proclined.



Happy patient!

